

Patient:
Date of Birth:
Scan Date:
Scan Location:
Referrer:
Reported By:
Report Date:


MEDICAL IMAGING
PARTNERSHIP
45 Queen Anne Street
London W1G 9JF
Tel: 020 3519 8998
Email:
reception@medicalimaging.org.uk

MRI Report

Indication: PSA 8-10. Hard on the left.

Technique: T2, diffusion-weighted & dynamic contrast-enhanced images of the prostate.

Findings: The prostate volume is 42cc.

2cc of tumour is seen in the left peripheral zone from apex (from level with, but not abutting uppermost sphincter) to base, medially extending to within 1mm of the midline and laterally (at the base) to 2cm from the posterior capsule. The associated enhancement extends to the extreme base, and here lies close to the left seminal vesicle without clearly involving it: a little linear enhancement extends as far as the vesicle but is little different to the other side, and overall vesicle involvement is fairly unlikely, though hard to completely rule out (2/5). There is extensive capsular abutment and although there is no measurable extracapsular extension, if there is a significant Gleason 4 component (which is likely) then there is a moderate chance of microscopic breach (but nothing to prevent surgery with appropriate margins).

The T2 signal in the right peripheral zone is patchy but the enhanced and diffusion images go against significant tumour. No evidence of transition zone tumour, seminal vesicle disease or pelvic lymphadenopathy.

Conclusion: Focal tumour on the left from apex to base.

Please see page 2 of this report for diagrams & representative images.

Sincerely,

Dr Alex Kirkham, Consultant Radiologist

Prostate Volume 42 CC

AP diameter: 3.8 cm

Transverse: 4.9 cm

Cranio-caudal: 4.3 cm

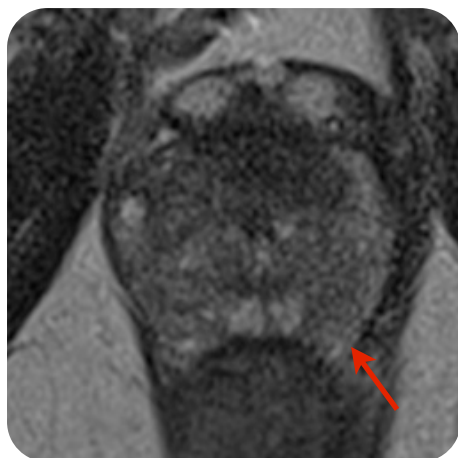
Scale 1= significant tumour very unlikely
 2= significant tumour unlikely
 3= equivocal
 4= significant tumour likely
 5= significant tumour very likely

**Significant tumour is defined as
>0.2cc or Gleason 3+4 or higher**

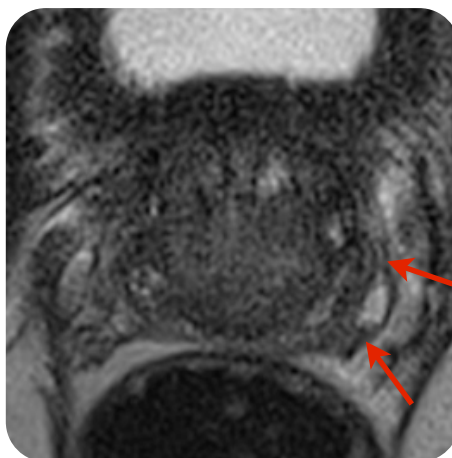
**Overall score
(for significant disease)**

	lat R	med R	TZ R	TZ L	med L	lat L
SV	1					2
base	2	2	2	2	4	5
mid	2	2	2	2	5	5
apex		2	2	2	5	
sphincter			1	2		

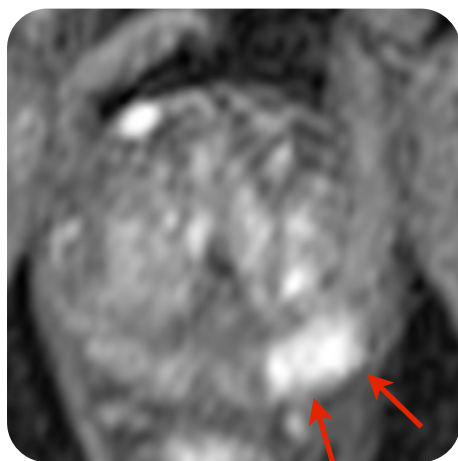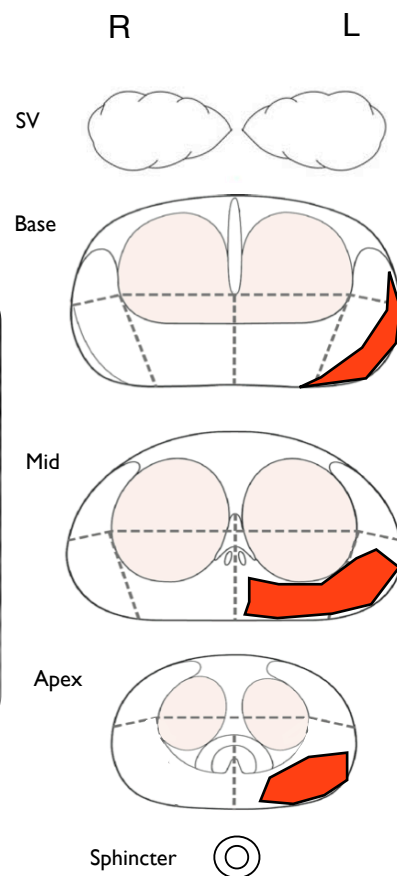
Patient:
Date of Birth:
Scan Date:



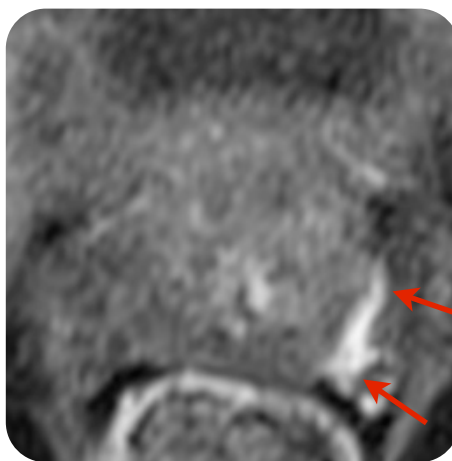T2 upper apex



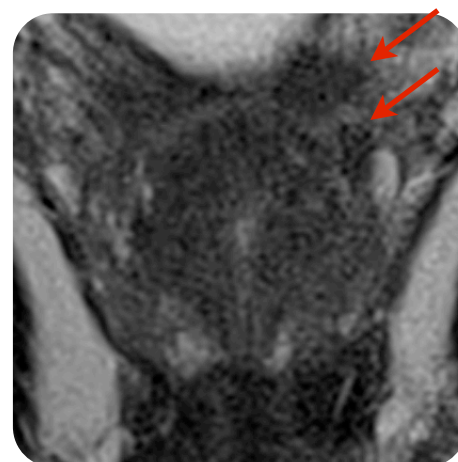T2 base



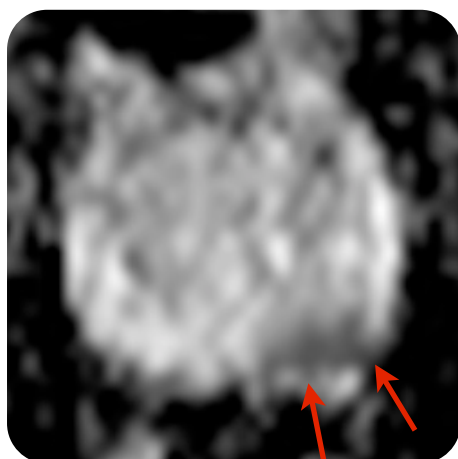
contrast lower mid



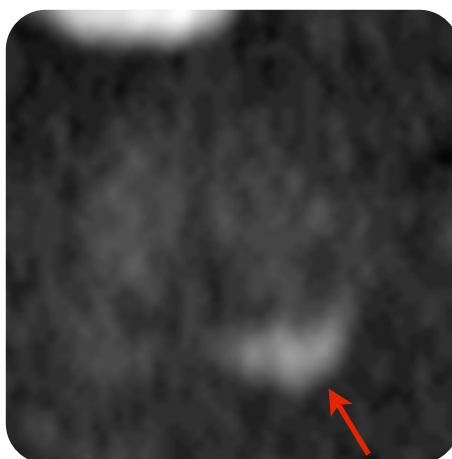
contrast base



T2 coronal: arrows show tumour and vesicle



ADC mid



long b mid