

Patient:
Date of Birth:
Scan Date:
Scan Location:
Referrer:
Reported By:
Report Date:


MEDICAL IMAGING
PARTNERSHIP
 45 Queen Anne Street
 London W1G 9JF
 Tel: 020 3519 8998
 Email:
reception@medicalimaging.org.uk

MRI Report

Indication: R sided cystic lesion scoring 3/5. PSA 8.3

Technique: T2, diffusion-weighted & dynamic contrast-enhanced images of the prostate.

Findings: The prostate volume is 93cc.

1. The cystic change in the right anterolateral prostate from base to apex has changed a little in configuration; in particular an area of T1 high signal (possibly blood) at the apex has become more loculated and now shows restriction. Tumour, however, is not considered likely and there is no convincing abnormal enhancement: still 2/5.

2. On the 2015 scan there was some patchy enhancement in the L peripheral zone. Today this is more focal in a 0.15cc focus posteriorly at mid gland, centred 1.6cm from the midline. However, in the absence of restricted diffusion we still score 2/5 for significant tumour.

3. We scored 3/5 in the L transition zone at mid gland in 2015, but i) on T2 the appearance is almost identical today, and generally heterogenous, and ii) the long b signal is little different. However, there is still around 1cc of restriction here on the ADC map, and it is a little more prominent today. For this reason we still score 3/5 and a further follow up scan would be useful (with the interval determined by the PSA).

No evidence of seminal vesicle disease or pelvic lymphadenopathy. The L testis lies a little high, but no focal lesion is seen within it.

Conclusion: The PSA density is not increased and we see no convincing tumour. However, two areas would be worth following up: the L transition zone at mid gland and the enhancement in the L posterolateral peripheral zone.

Sincerely, Dr Alex Kirkham, Consultant Radiologist

Prostate Volume 93 CC

AP diameter: 5.2 cm

Transverse: 6.6 cm

Cranio-caudal: 5.2 cm

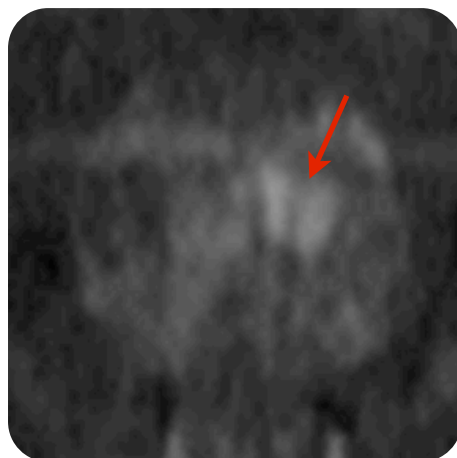
Scale 1= significant tumour very unlikely
 2= significant tumour unlikely
 3= equivocal
 4= significant tumour likely
 5= significant tumour very likely

Significant tumour is defined as
>0.2cc or Gleason 3+4 or higher

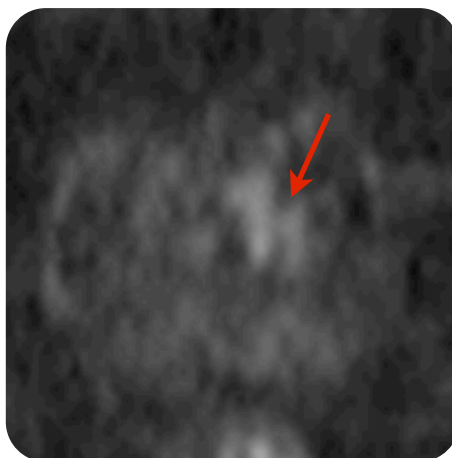
Overall score
(for significant disease)

	lat R	med R	TZ R	TZ L	med L	lat L
SV	1					1
base	2	2	2	2	2	2
mid	2	2	2	3	2	2
apex		2	2	2	2	
sphincter			1	1		

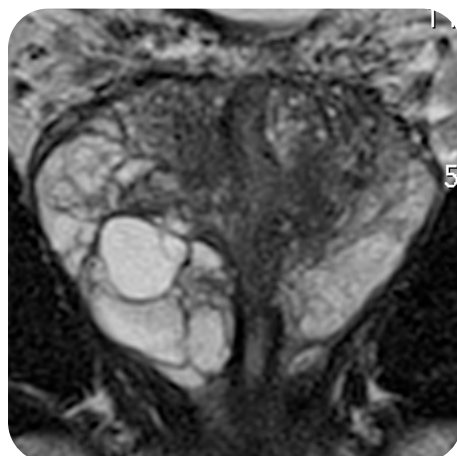
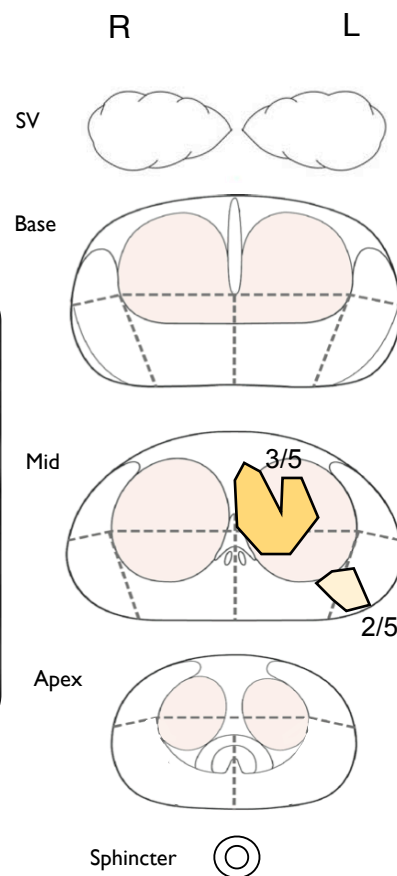
Patient:
Date of Birth:
Scan Date:
Report Date:



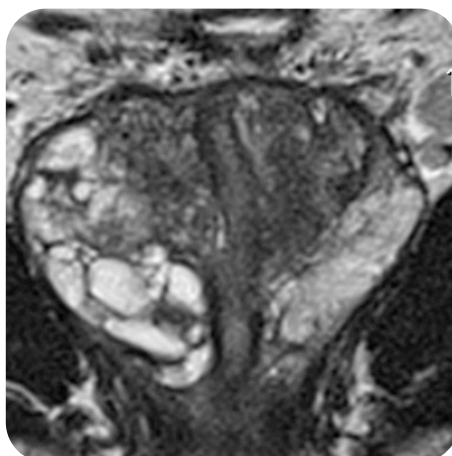
long b mid 2015



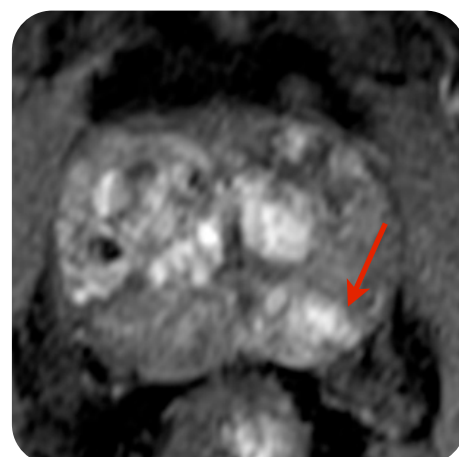
long b mid now



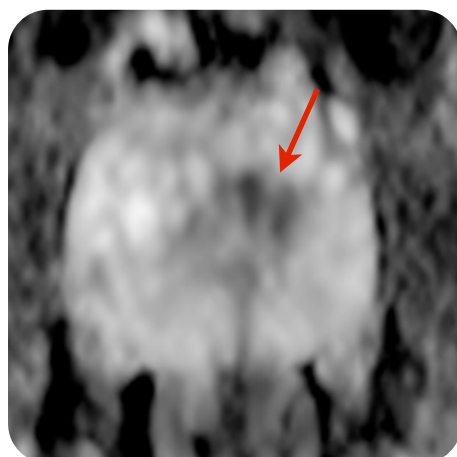
T2 coronal 2015



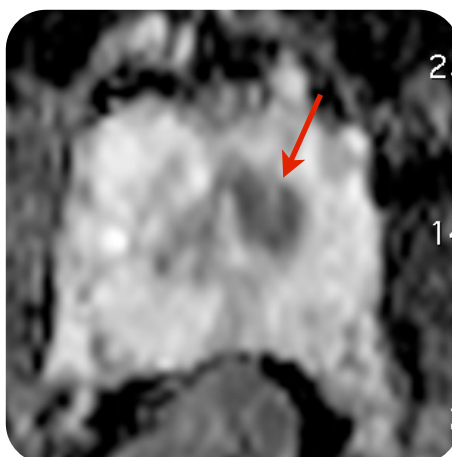
T2 coronal now



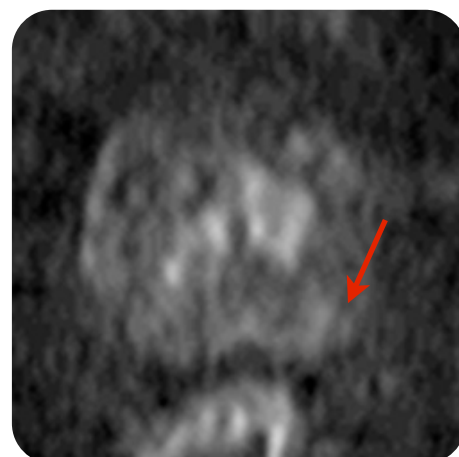
contrast axial mid now



ADC axial 2015



ADC axial now



long b axial now: no high signal posterolaterally on the left